

ACLAND'S VIDEO ATLAS OF HUMAN ANATOMY



“Getting Started” User Guide

**Have a question about
Acland's Video Atlas of Human Anatomy?**

Please contact Enterprise Support at
enterprisesupport@wolterskluwer.com

Or call 1-844-303-4860 (U.S) / 1-301-223-2454 (Global)

Hours (EST) of operation are:
8AM-12AM Monday-Thursday; 8AM-7PM Friday; 4PM-12AM Sunday

Introduction

Guide Objectives

This guide will help you:

- **Get started with Acland's Video Atlas of Human Anatomy**
 - System requirements
 - Obtain access
 - Sign in
- **Understand the features of Acland's Video Atlas of Human Anatomy**
 - Features
 - Navigating videos
 - Searching for videos
 - Glossary
 - Exams
 - About

System Requirements

Acland's Video Atlas of Human Anatomy is Lippincott's online platform for the delivery of more than 300 narrated videos of real cadaver specimens. Your subscription gives you anytime, anywhere access from your computer, smartphone, or tablet device.

Silverchair's browser support policy and currently supported browsers are as follows:

Supported Browsers. Silverchair supports the current and immediately prior versions of browsers that (i) are still supported by the browser vendor, (ii) have at least 5% user traffic in North America or globally, as determined by Silverchair, and (iii) have parity in function, or degrade gracefully when a feature is not supported natively ("Supported Browsers").

IE8 and IE10 are no longer officially supported by Microsoft on any desktop client operating system.

Browser	Current Version	Prior Version	Operating System	Global Usage (Updated Quarterly) 📅 01 Jan 2017	Silverchair Support	Vendor Support	End of Mainstream Support
IE9	N/A	N/A	Windows Vista SP2	5.96%	UNSUPPORTED	UNSUPPORTED	April 10, 2012
IE11	N/A	N/A	Windows 7 SP1	25.5%	UNSUPPORTED	UNSUPPORTED	January 13, 2015
IE11	N/A	N/A	Windows 8.1	25.5%	SUPPORTED	SUPPORTED	January 9, 2018
Edge			Windows 10	3%	SUPPORTED	SUPPORTED	October 13, 2020
Chrome			All		SUPPORTED	SUPPORTED	
Firefox			All		SUPPORTED	SUPPORTED	
Safari			Mac OS		SUPPORTED	SUPPORTED	



IMPORTANT: AclandAnatomy.com is **mobile optimized**. Apple iOS or Android devices are not required to have Flash Player installed; the videos will be served to your device in a non-Flash format.

Quick Start

Getting started is as easy as receiving access and signing in. You can immediately sign in and start using **Acland's Video Atlas of Human Anatomy**:

- Institutionally via IP authentication or referring URL, or
- Individually via online purchase or via a received/purchased access code.

Obtaining Access

Try it for yourself!

- You can register as an individual user for exclusive preview access to all the videos and complete functionality for 48 hours by visiting <http://aclandanatomy.com/> . After completing a brief online form, simply enter your user name and password to begin or retrieve your access to Acland's Video Atlas of Human Anatomy during the trial period.
- Faculty, librarians, and institutional administrators: please contact your local sales representative directly or complete the online [Institutional Request Form](#) to receive 30-day faculty or administrator access to sample videos and functionality.

You can subscribe!


- You will receive full access to all of the narrated videos to which your institution subscribes.
- Faculty, librarians, and institutional administrators: Contact your local sales representative directly to discuss subscription options and pricing for your institution, hospital, or organization. Or, complete the online [Institutional Request Form](#) to receive to submit a request for pricing.
- Individual-user subscriptions are also available and allow you to tailor your needs to the content offerings. Visit <https://store.aclandanatomy.com/> for more information on options and pricing.

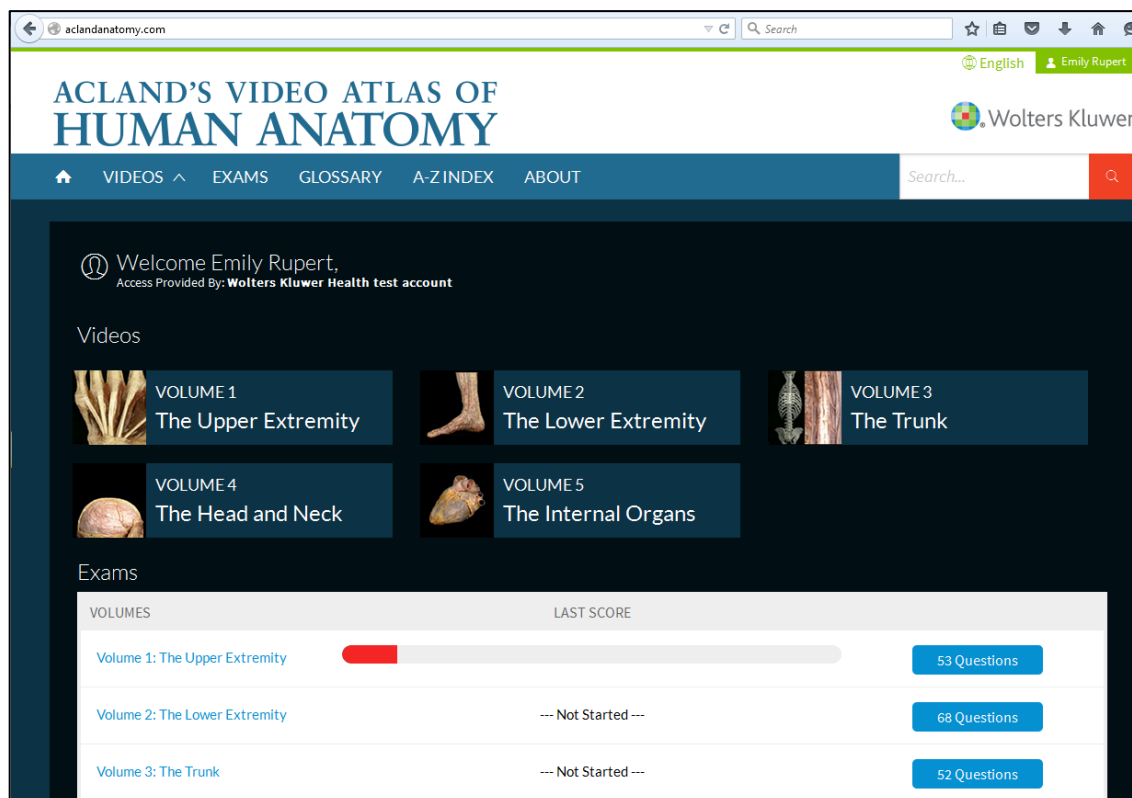
Signing In



QUICK TIP: *Forgot your password?* Click **Forgot your password?** at the bottom of the sign-in box and follow the prompts. Your password will be emailed to you. To change your password, sign in and click **My Account** at the top right of the page.

Forgot your username? Your email address serves as your username for the site.

- Once you have access to Acland's Video Atlas of Human Anatomy, go to <http://aclandanatomy.com/>
- On the welcome page, you will find the **Sign In** section. Enter your email and password, and click **Sign In**.
- The Acland's Video Atlas of Human Anatomy **home page** appears, and the volume(s) you have access to are displayed along with any exams you have started with associated scores and progress.
- To switch the language of a video and the website, click on the globe icon at the top of the site and select the language from the dropdown option. 



The screenshot shows the website interface for a user named Emily Rupert. The page title is "ACLAND'S VIDEO ATLAS OF HUMAN ANATOMY". The navigation menu includes "VIDEOS", "EXAMS", "GLOSSARY", "A-Z INDEX", and "ABOUT". A search bar is located on the right side of the navigation menu. The user is logged in, and the page displays a welcome message: "Welcome Emily Rupert. Access Provided By: Wolters Kluwer Health test account".

The "Videos" section displays five volume cards:

- VOLUME 1: The Upper Extremity
- VOLUME 2: The Lower Extremity
- VOLUME 3: The Trunk
- VOLUME 4: The Head and Neck
- VOLUME 5: The Internal Organs





















The "Exams" section displays a table with columns for "VOLUMES" and "LAST SCORE".

VOLUMES	LAST SCORE
Volume 1: The Upper Extremity	53 Questions
Volume 2: The Lower Extremity	--- Not Started ---
Volume 3: The Trunk	--- Not Started ---

Features

Navigating Videos

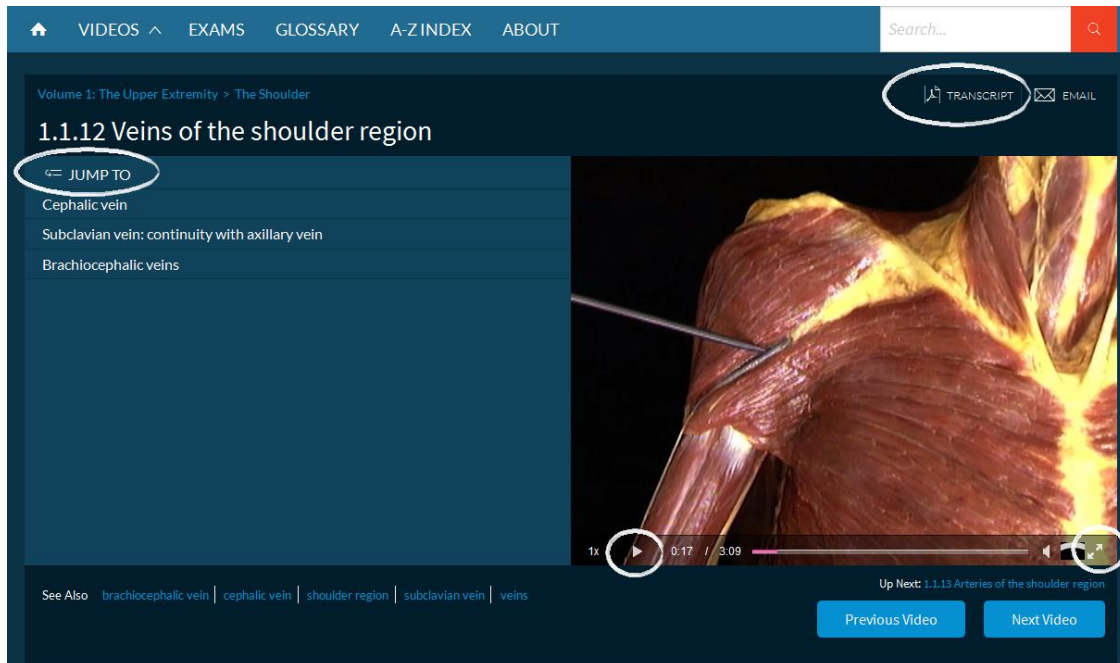
- You can navigate the videos by volume; each volume is further divided by region for ease of selection and reference in syllabi/ lectures.
- Each video is listed below its corresponding region, along with video number, title, and length.
- Click on the video link you wish to view. Individual video links may be added to notes, syllabi, and lectures by including the URL hyperlink. A list of URLs for each video is available at the bottom of the About page [here](#).

 VOLUME 1 The Upper Extremity	— The Shoulder	
 VOLUME 2 The Lower Extremity	 1.1.1 Introduction to the shoulder region (0:30)	 1.1.9 Latissimus dorsi, pectoralis major and deltoid muscles (2:48)
 VOLUME 3 The Trunk	 1.1.2 The clavicle and scapula (4:11)	 REVIEW 1.1.10 Review of shoulder muscles (1:15)
 VOLUME 4 The Head and Neck	 1.1.3 Movements of the clavicle and scapula (0:59)	 1.1.11 Landmark structures for nerves and blood vessels (2:29)
 VOLUME 5 The Internal Organs	 1.1.4 The shoulder joint and its movements (1:43)	 1.1.12 Veins of the shoulder region (3:09)
	 REVIEW 1.1.5 Review of bones, joints, and ligaments of the shoulder (1:17)	 1.1.13 Arteries of the shoulder region (2:35)
	 1.1.6 Introduction to shoulder muscles (0:23)	 1.1.14 Nerves of the shoulder region: the brachial plexus (5:33)
	 1.1.7 Muscles passing from the scapula to the humerus (3:48)	 REVIEW 1.1.15 Review of blood vessels and nerves of the shoulder region (2:26)
	 1.1.8 Muscles passing from the trunk to the scapula (3:58)	
	+ The Arm and Forearm	
	+ The Hand	



QUICK TIP: Want to share a video? Click **EMAIL** in the right hand corner of the video window and follow the prompts to share a video with peers, colleagues, or students.

- An expanded table of contents for each video is listed in the panel on the left side of the video window, allowing you to **Jump To** specific parts of the video. You can also slide forward or backward on the video seek bar.
- Below the video window, the video player allows you to:
 - Start and stop each video by clicking the **Play** or **Pause** button.
 - **Adjust the video speed** from to 1.5x or 2x.
 - Expand the video to **full-screen**.
 - Adjust the **volume** of the audio narration.



- View the Previous Video or Next Video by clicking on the corresponding blue buttons on the bottom right below the video window.
- View a PDF transcript of the narrative for each video by clicking the **Transcript** link in the right-hand corner of the video display box.

1.1.12
Veins of the shoulder region
(3:09)

Let's start by looking at the veins. We can be quite brief about this since the veins parallel the arteries in most important respects. It'll be helpful to start on the outside and progress inward, removing some muscles as we go along.

Here, in the groove between pectoralis major and deltoid, is the cephalic vein, coming up from the arm. It's a vein that doesn't have an accompanying artery. To see where it's going, we'll remove pectoralis major.

Here's the cephalic vein. Together with other veins from the shoulder region, it joins the main vein of the upper extremity, the subclavian vein. We'll focus our attention on this important vein. The subclavian vein comes up from the arm and passes beneath pectoralis minor. Emerging from beneath pectoralis minor, it passes over the outer surface of the first rib (here's the first rib) and under the subclavius muscle and the clavicle. To follow the subclavian vein further, we'll remove the clavicle, the subclavius muscle, and this muscle, the sternocleidomastoid.

- Key terms related to each video are listed on the bottom left side of the video window under **See Also**.
- After clicking on a key term, a list of related videos populates.

Volume 1: The Upper Extremity > The Shoulder

1.1.12 Veins of the shoulder region

← JUMPTO

Cephalic vein

Subclavian vein: continuity with axillary vein

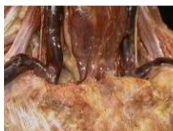Brachiocephalic veins



See Also [brachiocephalic vein](#) | [cephalic vein](#) | [shoulder region](#) | [subclavian vein](#) | [veins](#)

Search Results for brachiocephalic vein

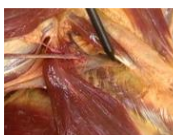Showing 1 – 9 of 9



3.2.12 Superior vena cava, **brachiocephalic veins** (3:27)

principal **vein** of the head and neck, here, behind the medial end of the clavicle, forming the **brachiocephalic vein**. The two **brachiocephalic veins** enter the thorax and unite, forming the superior vena cava. To see the subclavian and internal jugular **veins**, we'll remove the major muscles which lie in front ...

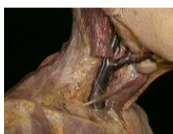Tags: [brachiocephalic vein](#), [subclavian vein](#), [internal jugular vein](#), [superior vena cava](#), [pleura](#)



1.1.12 **Veins** of the shoulder region (3:09)

joined from above by the main **vein** of the head and neck, the internal jugular **vein**. Together the subclavian and internal jugular **veins** form the **brachiocephalic vein**. The **brachiocephalic vein** passes medial to the first rib, and enters the chest. The dome of the pleura lies immediately behind it; here's ...

Tags: [brachiocephalic vein](#), [shoulder region](#), [veins](#), [cephalic vein](#), [subclavian vein](#)



4.9.10 **Veins** of the neck and face (3:35)

jugular **vein** continues down the neck, behind the common carotid artery and lateral to it. It's crossed by the omohyoid muscle. Down here behind the clavicle the internal jugular **vein** ends by joining with the subclavian **vein** to form the **brachiocephalic vein**. As shown in Tape 3, the two **brachiocephalic** ...

Tags: [neck](#), [tissue dissection](#), [veins](#), [internal jugular vein](#), [facial veins](#), [sternocleidomastoid muscle](#), [external jugular vein](#)

- A brief, integrated **video review** appears at the end of each region that allows you to quickly review what you learned. Each video recaps important structures and objectives for test preparation and knowledge reinforcement.

The Shoulder

- 1.1.1 Introduction to the shoulder region (0:30)
- 1.1.2 The clavicle and scapula (4:11)
- 1.1.3 Movements of the clavicle and scapula (0:59)
- 1.1.4 The shoulder joint and its movements (1:43)
- 1.1.5 Review of bones, joints, and ligaments of the shoulder (1:17)**
- 1.1.6 Introduction to shoulder

Searching Videos

- **Keyword search:** Type a key term in the upper right hand corner search box and click search. Search results will automatically populate.

ACLAND'S VIDEO ATLAS OF HUMAN ANATOMY

Wolters Kluwer

HOME VIDEOS ^ EXAMS GLOSSARY A-Z INDEX ABOUT

Scapula

A-Z Index

- **A-Z index:** Click on **A-Z Index** on the tool bar menu and an alphabetical index is displayed. Click on a term in the index and specific video results are presented.

The screenshot shows the website's navigation bar with 'A-Z INDEX' circled. Below the navigation bar, the 'A-Z INDEX' page is displayed. It features a search bar with the placeholder 'type to filter' and a 'JUMP TO:' section with a list of letters from A to Z. The main content area lists anatomical terms under the letter 'A', including: abdomen, abdominal arteries, abdominal cavity, abdominal muscles, abdominal veins, abducent nerve, abductor digiti minimi muscle, accessory nerve, acetabulum, acromioclavicular joint, anal sphincter, external, and ankle joint ligaments.

Glossary

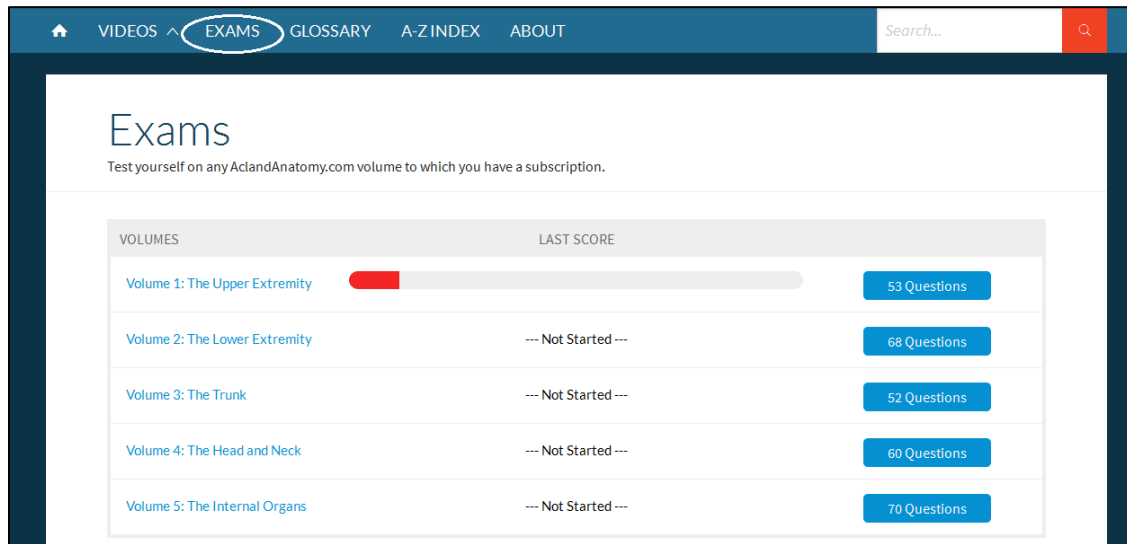
- Click **Glossary** on the tool bar menu and an alphabetical list of anatomical terms populates, along with the origin and translation.

The screenshot shows the website's navigation bar with 'GLOSSARY' circled. Below the navigation bar, the 'Glossary' page is displayed. It features a search bar with the placeholder 'type to filter' and a 'Jump to:' section with a list of letters from A to Z. The main content area contains a table of anatomical terms, their Latin origins, and their translations. The table is as follows:

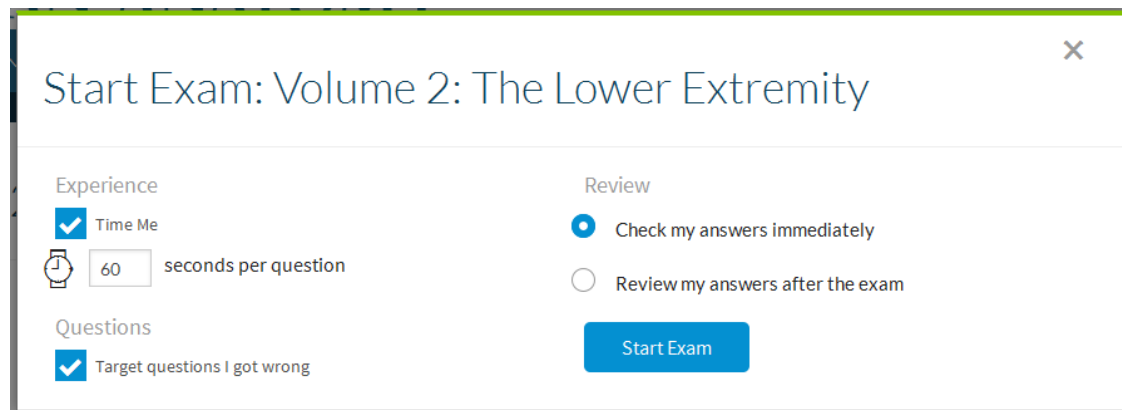
Term	Origin	Translation
Abduct	LATIN	<i>ab</i> , away + <i>ducere</i> , pull.
Acetabulum	LATIN	<i>acteu</i> , vinegar + <i>abrum</i> , holder. Small cup for vinegar, hence any small cup.
Adduct	LATIN	<i>ad</i> , towards + <i>ducere</i> , pull.
Adrenal	LATIN	<i>ad</i> , toward + <i>ren</i> , kidney.
Ala (alar)	LATIN	<i>ala</i> , wing.
Alveolus (alveolar)	LATIN	<i>alveolus</i> , small compartment.
Ampulla	LATIN	<i>ampulla</i> , flask.
Ansa	LATIN	<i>ansa</i> , handle.
Antecubital	LATIN	<i>ante</i> , in front; <i>cubitum</i> , elbow.
Anular	LATIN	<i>anus</i> , ring.
Appendix	LATIN	<i>ad</i> , toward; <i>pendere</i> , to hang. Hence appendage.
Aruate	LATIN	<i>arcus</i> , bow.

Exams

- Click **Exams** on the tool bar menu to test yourself on any volume to which you have a subscription; in this example, all 5 volumes are shown. Then, click on the Start button.



- There are options for self-testing:
 - **Time Me:** Select this option to be timed (60 seconds per question) to mimic an exam experience.
 - **Target questions I got wrong:** Click on this option to receive questions you answered incorrectly in previous exams
 - **Review:** Chose to see the answers and receive video links for review immediately after answering each question (Review Mode) or to check your answers at the end of the exam (Exam Mode) within an itemized list.



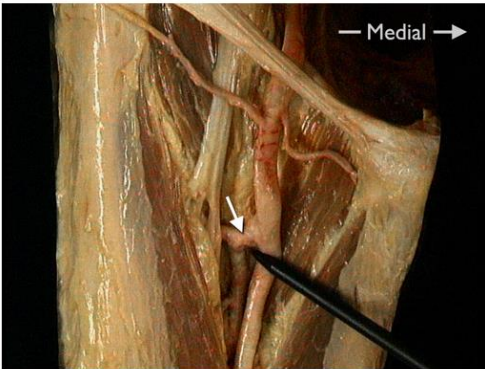
- **Review Mode:** Upon answering the question, the correct answer is displayed, along with a link to a supporting video for further review.

Exams > Volume 2: The Lower Extremity

Volume 2: The Lower Extremity

Save Exam & Review Later

2 Incorrect | 0 Correct | 66 Unanswered



In this anterior view of the right femoral triangle, identify the artery indicated by the arrow.

- A Deep femoral
- B External pudendal
- C Femoral
- D Lateral circumflex femoral
- E Superficial circumflex iliac

Next Question

Review the following clip for the correct answer:
2-1-14-40 External pudendal artery; Superficial circumflex iliac artery (timestamp 00:52).

- **Timed Mode:** You have 60 seconds to answer each question. The time is displayed and counts down at the top right. Once the 60 seconds has expired, the clock will turn red.


Exams > Volume 2: The Lower Extremity

Volume 2: The Lower Extremity

Save Exam & Review Later

68 Unanswered

00:07



In this medial view of the right leg, identify the muscle indicated by the arrow.

- A Fibularis (peroneus) longus
- B Gastrocnemius
- C Plantaris
- D Soleus
- E Tibialis anterior

Submit Answer Skip & Answer Later

Save Exam & Review Later

- If you want to save and exit your exam, click **Save Exam & Resume Later** in the upper right corner of the test window. You may access your **Exam History** and **Resume** exams on each Volume's Exam screen.

Exams

Volume 3: The Trunk

LAST EXAM TAKEN

Start a New Exam Start

Exam History

STARTED	COMPLETED	MODE	SCORE
08/27/2015	---	Exam	---
06/19/2015	---	Review	---

52 QUESTIONS LAST SCORE

4 Incorrect | 1 Correct | 47 Unanswered

08/27/2015 Exam Mode

- Upon completion of the exam, your score is displayed with an itemized list of questions answered correctly and incorrectly along with **Recommended Viewing** in the right-hand column of the window. These suggested videos help improve exam performance and target your review of those topics that require additional study.
- The color bar along the top indicates visually correct (blue) and incorrect (red) answers. You can filter the data to focus your review.

Volume 3: The Trunk

08/14/2015 2 min 45 sec Exam Mode

52 QUESTIONS 19% SCORE

Filter By All 42 Incorrect 10 Correct

1. 0:07 **Incorrect**

In this internal view of the lateral wall of the pelvis, identify the structure indicated by the arrow.

A Inferior gluteal artery

B Internal iliac artery

C Internal pudendal artery

D Superior gluteal artery

E Ventral ramus of S1

Review the following clip for the correct answer: 3-4-8-68 Superior gluteal artery (timestamp 01:10).

2. 0:07 **Incorrect**

Identify the structure at the tip of the arrow

A Anulus fibrosus

B Capsular ligament

Recommended Viewing

Based on your performance on this exam, the following videos are recommended as study aids.

The Spine

3.1.1 The vertebral column, features of a typical vertebra

Question 3: See timestamp 03:35

Question 12: See timestamp 03:35

Question 17: See timestamp 03:35

Question 25: See timestamp 04:04

The Spine

3.1.3 Lumbar vertebrae, sacrum

Question 14: See timestamp 02:17

Question 36: See timestamp 00:00

Question 50: See timestamp 02:17

The Spine

3.1.4 Ligaments of the vertebral column, intervertebral disks

About

- Click **About** on the tool bar menu to learn about the origins of the video atlas project, how it came together, who benefits from this three-dimensional learning experience, and the features that make it unique.



ACLAND'S VIDEO ATLAS OF HUMAN ANATOMY

Wolters Kluwer

VIDEOS ^ EXAMS GLOSSARY A-Z INDEX ABOUT Search...

ABOUT

User Guide

Who Is It Intended For?

How The Project Began

Seeing and Learning in Three Dimensions

How the Atlas Was Made

Unique Features

VOLUME 1
The Upper Extremity

VOLUME 2
The Lower Extremity

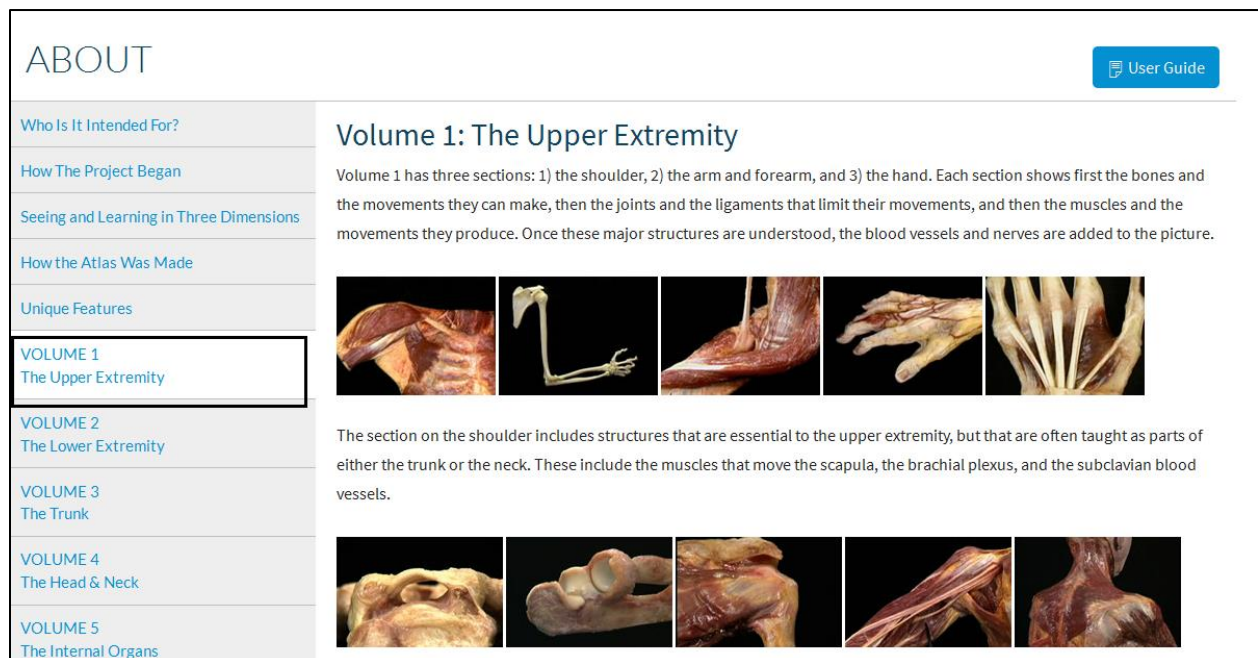
Who Is It Intended For?

The Video Atlas was originally intended to be used by individual medical and dental students. Because of its realism, simple language, and three-dimensional quality, the Video Atlas has become popular with students and teachers in many other fields and also with people not on a professional learning path who are looking for information about human anatomy.

Medical and dental students.

In first-year studies, the Video Atlas is productive and time efficient as a preview, as an adjunct to dissection, and as a review tool. It is also helpful for students who need to re-learn clinically relevant anatomy for their surgical rotations. Since surgeons in training must re-learn anatomy at many stages in their careers the Video Atlas is popular with interns and residents in surgical specialties.

- Click a volume to learn about the content covered in each volume.



ACLAND'S VIDEO ATLAS OF HUMAN ANATOMY

Wolters Kluwer

VIDEOS ^ EXAMS GLOSSARY A-Z INDEX ABOUT Search...

ABOUT

User Guide

Who Is It Intended For?

How The Project Began

Seeing and Learning in Three Dimensions

How the Atlas Was Made

Unique Features

VOLUME 1
The Upper Extremity

VOLUME 2
The Lower Extremity


VOLUME 3
The Trunk

VOLUME 4
The Head & Neck


VOLUME 5
The Internal Organs

Volume 1: The Upper Extremity

Volume 1 has three sections: 1) the shoulder, 2) the arm and forearm, and 3) the hand. Each section shows first the bones and the movements they can make, then the joints and the ligaments that limit their movements, and then the muscles and the movements they produce. Once these major structures are understood, the blood vessels and nerves are added to the picture.



The section on the shoulder includes structures that are essential to the upper extremity, but that are often taught as parts of either the trunk or the neck. These include the muscles that move the scapula, the brachial plexus, and the subclavian blood vessels.



- A list of URLs for each video is available at the bottom of the About page [here](#).